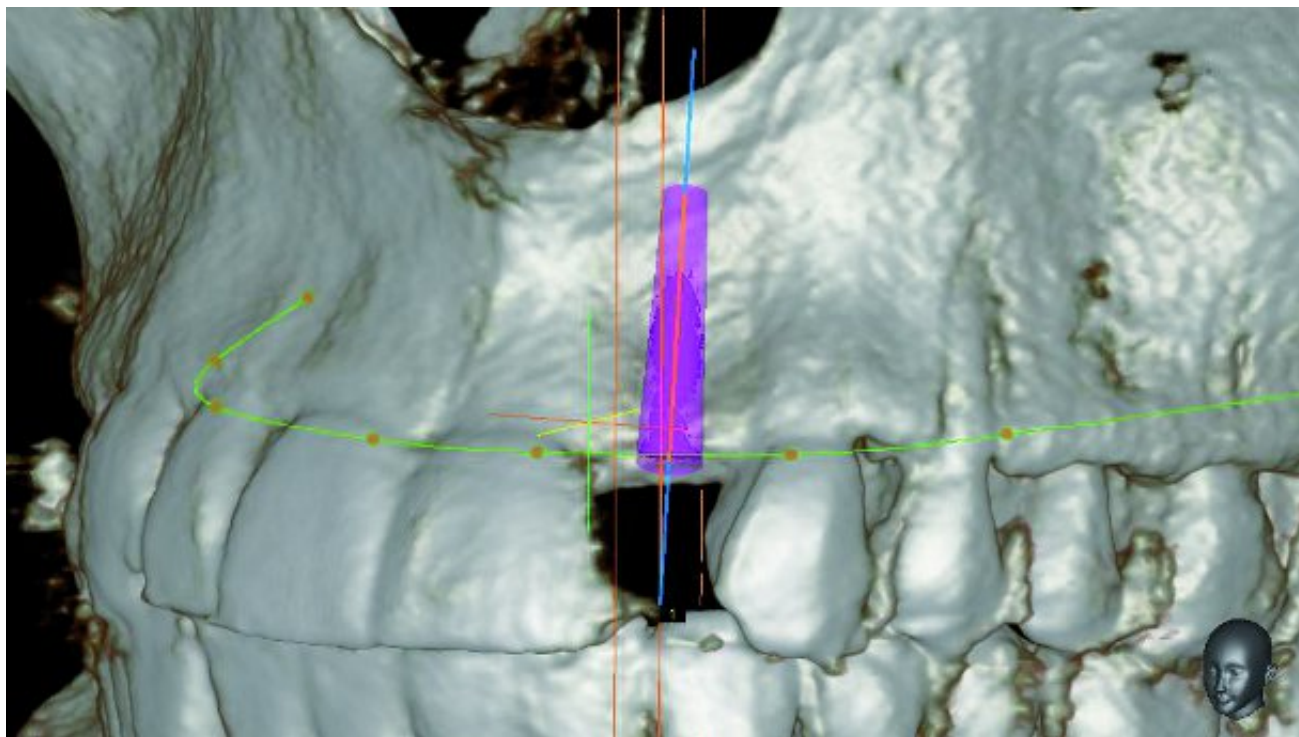


# DENTAL TRIBUNE

— The World's Dental Newspaper —

## Clinical Implantology



Evidence of bone deficit at 22

23 juil. 2015 | Implantology International

## Lateral maxillary incisor implant – Key issues for aesthetic success

by Drs Philippe Russe & Patrick Limbour, France

**Faced by a missing lateral incisor, practitioners often consider a wide range of issues and are also faced by numerous treatment options:**

- 1. in a young patient, faced with a unilateral or bilateral agenesis, he has to choose between an orthodontic treatment that either opens up the spaces or closes them. This decision, when taken early in the overall treatment, will affect both the patient and their caregiver for a long time (Fig. 1);**
- 2. in an adult patient, this is a consequence of bone, physiological, traumatic or infectious**

## resorption, which will result in a decision whether or not to recommend a bone reconstruction or a gingival augmentation.

was written by:



Dr. Philippe Russe

In every situation, the results will be judged by the patient and those around him. Since the lateral maxillary incisor is an integral part of the smile, aesthetic expectations are generally very high and, if the results do not meet the expectations, disappointment can be powerfully felt.

When describing the different treatment stages, a number of pitfalls and difficulties will be highlighted and advice and clinical protocols will be given, in order to ensure that the results of this implant/prosthetic treatment are predictable and as aesthetically attractive as possible. This first article is concerned with these issues as regards the preprosthetic stages; the second will consider the most important aspects of the prosthetic stages as well as aesthetic outcomes and their evolution over the long term.

### *Anamnesis*

Once the usual contraindications for oral and implant surgery have been eliminated, particular attention should be given to the patient's answers concerning their smoking habits. Indeed, meta-analysis give an accurate picture of the consequences of smoking, with increases of:

peri-implantitis[1,2] and bone loss[2];  
failure rates.[3]

The conclusions of Snider et al.[4] can provide recommendations for the practitioner faced with a patient who is a smoker:

the best is to ask the patient to stop smoking...;  
if this approach is not acted on, then the patient must be warned of the increased risk of failure and of postoperative complications.

This last issue is important, as smoking can be considered a lost opportunity as far as implant treatment is concerned.

**“It is preferable to avoid patients that are smokers.”**

### **Clinical examination**

#### *The smile line*

When replacing a tooth in an aesthetic region, understanding the location of the smile line is one of the determining issues during the clinical examination. There are two factors to consider: the exposure of papillae and visibility of the collar of the lateral incisor, and there is one significant problem: any aesthetic deficit experienced by the patient tends to make them change their smile line, which can happen more or less as a conscious process and this can be a source of significant errors. Analysis of gingival composition is also a determining issue in positioning the collar of the lateral incisors in a location that is aesthetically optimal. The gull-wing profile, where the collar of the lateral incisors is slightly more coronal than that of the front teeth or the canine teeth, is considered to be more attractive according to Chiche[5] (Fig. 2).

#### *Dental aesthetics*

As regards dental aesthetics, the proportions of the proposed implant supported tooth can reflect

two different scenarios:

there is a unilateral missing tooth and the contralateral incisor has normal and aesthetically pleasing proportions. The objective will be to create a lateral incisor implant that is a mirror image;

with the same situation but where the contralateral incisor is small; this is a situation that occurs frequently in unilateral agenesis where the incisor that is present is rizziform or, if there is agenesis of both lateral incisors, the clinical examination should gather the information required to decide on the dimensions and coronal axes of the proposed lateral incisors. An analysis of the occlusion and the dimensions of the central incisors are the clinical parameters that make it possible to establish the characteristics of the planned prosthetic teeth.

The anatomy of the lateral incisor has been the subject of various publications, including, notably, by Papathanassiou[6] who defined average dimensions and a typical form (Fig. 3a) and also presented numerous morphological variants affecting these dimensions and also other characteristics such as the crown/root ratio and the coronal and root axes (Fig. 3b). These morphological criteria, which can now be found using 3-D imaging, have had a significant influence on the location of implants in all spatial planes in order to achieve the goal of harmony of form and dimension. Other publications, such as those by Levin[8] and Preston[8] make it possible to estimate the width of absent lateral incisors on the basis of the central incisors (Fig. 4).

**“Establish the ideal width and orientation of the planned prosthetic crown.”**

#### *Implant location*

A clinically significant deficit signals the need for reconstruction of hard tissue but, conversely, a site without a tooth with no loss of volume should be subjected to a three-dimensional X-ray, as thick soft tissue can hide a lack of hard tissue (Fig. 5). A thin tissue biotype or a lack of attached gingival can be a sign that gingival augmentation surgery will be required, particularly if a bone graft needs to be performed.

#### *Occlusion*

For orthodontic treatments, the anterior guidance should be analyzed carefully. It can be tempting to increase the perimeter of the maxillary arcade in order to obtain, at the least, implant corridors that are sufficiently wide at the level of 12 or 22. However, an overjet will make it very likely that the natural teeth will move in relation to the implant prosthesis with highly negative consequences for the sustainability of the cosmetic outcome.

#### *Documentation*

Taking photographs at the start of the treatment will make it possible to maintain a record of the initial condition, which is always useful if there are medical/legal problems at the end of the treatment. In addition, the images often make it possible to see problems relating to width, axis or asymmetry that sometimes go unnoticed during a clinical examination.

**“Check anterior guidance and absence of overjet.”**

### **Complementary tests**

#### *2-D imaging*

Panoramic X-rays or retroalveolar radiography make it possible to check the depth of implantable bone in relation to the floor of the nasal cavity, the bone level in relation to that of adjacent teeth

and the parallelism of the central incisor and canine.

### *3-D imaging*

3-D imaging is required to check the vestibular palatal dimensions of the bone crest. There are three possibilities:

- the crest is sufficiently wide to take an implant without any bone augmentation;
- the crest is narrow, bone augmentation is required prior to siting the implant (Fig. 6);
- intermediate situations where the siting of the implant will be accompanied either by bone splitting or by guided bone regeneration.

### **Orthodontic preparation**

When the adjacent teeth present apical convergence, the orthodontic preparation should create a mesio-distal dimension at the level of the root that allows the implant to pass with a margin of at least 1 mm of bone (Figs. 7 & 8). Where there is a controlateral incisor of a normal size, the rule for the orthodontist is to measure the width of that tooth carefully and to recreate the same width in the crown of the planned implant. Where the controlateral incisor is riziform, the orthodontist should plan the future face of the tooth in order to achieve two laterals with the same shape.

Diastemas around the riziform tooth make it possible to achieve a smile that, in the end, is almost symmetrical (Fig. 9). The riziform incisor does not have to be in the centre of the space but should be positioned in such a way that the papillae and the future zenith of the tooth are optimized. The zenith should be located 0.4mm distal from the centre of the tooth for a lateral incisor, according to Chu et al.[9] (Figs. 10a & b). Sometimes, a zenith situated more than 1 mm from a line between the collars of the central incisor and the canine should be surgically altered by coronal lengthening as a lateral incisor that is too short can also be aesthetically unacceptable.

**“The orthodontist should anticipate the future prosthetic morphology of the riziform incisor.”**

### **Hard tissue augmentation**

Where a bone reconstruction is indicated, this should take into account one of the key factors for the overall cosmetic outcome: restoration of papillary support in order to avoid any unsightly black triangles between the lateral incisor and the adjacent teeth or any concave area above the implant crown that would create an ugly shadow.

The cortical graft, taken from the chin or the external oblique, should be formed in such a way as to provide support for the gingival papillae (Fig. 11). Gaps under and around the graft should be filled with cortical bone particles, crushed from the chin block or lateral mandibular area using a bone mill.

The attachment must be reliable. This is done using two 1.6mm diameter osteosynthesis screws (Fig. 12). Autografts take about 5 months to heal. Ideally, the implant should be inserted between 4.5 and 5.5 months after the graft (Fig. 13).

**“Fully reconstruct papillary support.”**

### **Insertion of implant**

#### *Choice of implant*

The mesio-distal dimension of the gap will determine the choice of the implant. When this is close

to or less than the average size of 6.5 mm, the bone and papillary volume around standard size implants will be limited. According to Hasan et al.[10] and Bourauel et al.,[11] the disadvantage of small diameter implants is that they transmit higher stresses to the crestal bone than do standard implants. When replacing a lateral maxillary incisor, it is possible to arrange both the anterior guidance and the deduction in such a way as to make them largely affect the natural teeth, in the absence of any significant malpositioning, and in this way reduce the stresses applied to the implants. Under these conditions, small diameter implants have the advantage of increasing surrounding residual bone volume as well as space available for papillary healing.

In a forthcoming study of 120 Nobel Active 3 mm diameter implants, one of the conclusions confirmed the importance of these small diameter implants as regards the additional height of the papillae, resulting in an improvement in the Fürhauser pink aesthetic score[12] (Figs. 14, 15a & b).

### **“Favor small diameter implants.”**

#### *3-D positioning*

As regards replacement of a lateral maxillary incisor, the tolerances for the location of the implant are very small because of the narrow width of the implant corridor. Two recent meta-analysis[13,14] concerning the precision of surgical guides resulting from 3-D imagery, even if these do not apply specifically to the lateral incisor replacement, has found a deviation in the order of a millimetre at the point the implant emerges and 4 to 5 degrees as regards the drilling axis. For Van Assche et al.,[14] the average imprecision at the apex of the implant is 1.24 mm.

Since these measurements are incompatible with a 12 or 22 implant corridor, it is important to check the first drill hole(s) during the operation, whether the surgery is guided or being carried out freehand. If the implant clinic does not have retroalveolar X-ray equipment, portable generators such as the Anyray 2 ([Vatech](#)) are available on the market, which allow you to produce intraoperative images (Fig. 16).

In this context the Precision Drill from the [Nobel Biocare](#) kits is particularly helpful. Its sharp point provides considerable precision at the point of entry and its small dimensions make it possible to correct any deviations from the ideal axis occurring during the first drilling (Fig. 17).

In the vestibular palatal plane, it is essential to prepare a prosthetic treatment plan before inserting the implant because the positioning requirements differ:

for a screwed prosthesis, the axis of the implant is very strictly determined by the point in the cingulum where the screw emerges;

with a cemented prosthesis, the tolerance is slightly greater as it is possible to make a correction to the axis by an abutment angled up to 15 degrees or by a Procera type individualized abutment (Fig. 18).

### **“Position the implant under X-ray monitoring.”**

#### **Soft tissue management**

Whether the soft tissue management is carried out at the time the implant is put in place or when it is exposed, the choice of surgical technique depends on an examination of the initial situation:

horizontal deficit of soft tissue that could result in the underlying titanium being visible;

vertical deficit in the papillae that could result in unsightly black triangles.

Different surgical techniques can be used, depending on these deficits, which are taken from three

publications: the roll flap developed by Abrams,[15] the envelope technique of Peter Raetzke[16] and Carl Misch's split-finger:[17]

if there is just a horizontal deficit, a modified rolled Flap[6] can be carried out, without separation of papillae and without vestibular incisions, the palatal flap being folded into an envelope flap (Figs. 19 to 25). The attraction of this technique for the patient is that a second operation site to take a graft is not required. In addition, it makes it possible to recreate a root eminence, considered already 20 years ago by Silverstein and Lefkove[18] to be an important factor for the aesthetic outcome (Figs. 26 & 27a to c);

where there is a vertical deficit, a crestal W-shaped incision as described by Carl Misch[17] is indicated. This makes it possible to recreate an anatomical gingival architecture while, as a first step, creating two vestibular neo-papillae (Fig. 28). After separating the sections, the palatal tissue (finger) is divided into two to make two palatal half-papillae, joined one on one with their vestibular counterparts (Fig. 29);

where there is a combined deficit, the same incisions are combined with a buried connective vestibular graft. Provided that there is sufficient volume, the graft is taken from the maxillary tuberosity, since this area has the advantage of providing graft tissue that is more dense, opaque and less adipose than the palate and, in addition, results in less postoperative pain. If the graft is transferred in a V- or Y-shape, it can support the newly formed papillae. The shape of the palatal incision can be modified to a Y-shape to assist rotation of the palatal half papilla (Fig. 31).

If the thickness of the buccal gingival tissues has not been augmented or if collagen substitutes are used that do not have the opacity characteristics of tuberosity connective tissue, the aesthetic outcome can be compromised. If there is recession of the external table or the titanium abutment under thin connective tissue, the grey titanium colour can be seen through the gum as a grey halo above the crown collar, which is detrimental to the aesthetic appearance (Figs. 32 & 33).

**“Systematically augment the thickness of buccal connective tissue.”**

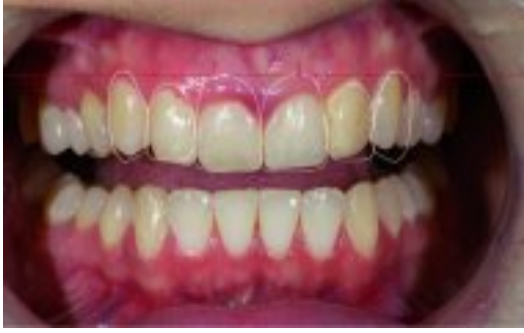## Conclusion

The aesthetic fundamentals for an implant are in the preprosthetic surgical stages of the treatment. Any approximation in the location of the implant in such a narrow implant corridor, any lack of support for papillae or any deficiency in the thickness of hard or soft tissues, will result in aesthetic problems. The prosthetic stages allow optimisation of the result as regards the gingival context but any error in the surgical stage will often be impossible to correct during the prosthetic stages. For this reason it is vital to approach this first part of the implant treatment for a lateral incisor with thoroughness and precision.

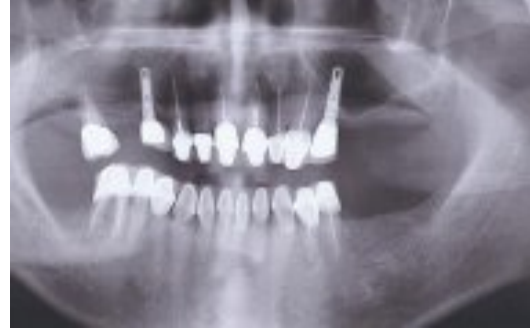*Editorial note: A complete list of references is available from the publisher.*

*This article was originally published in the Éditions CdP prosthetic journal, No 167, September 2014, the [Clinical Masters Magazine No 1/2015](#) and the [cone beam – international magazine of cone beam dentistry No 2/2015](#).*

**Read More**



28 oct. 2015 | Implantology International  
**Digital implantology— Predictable  
aesthetics and functional results**



11 avr. 2013 | Implantology International  
**Prevention of failures in oral  
implantology**